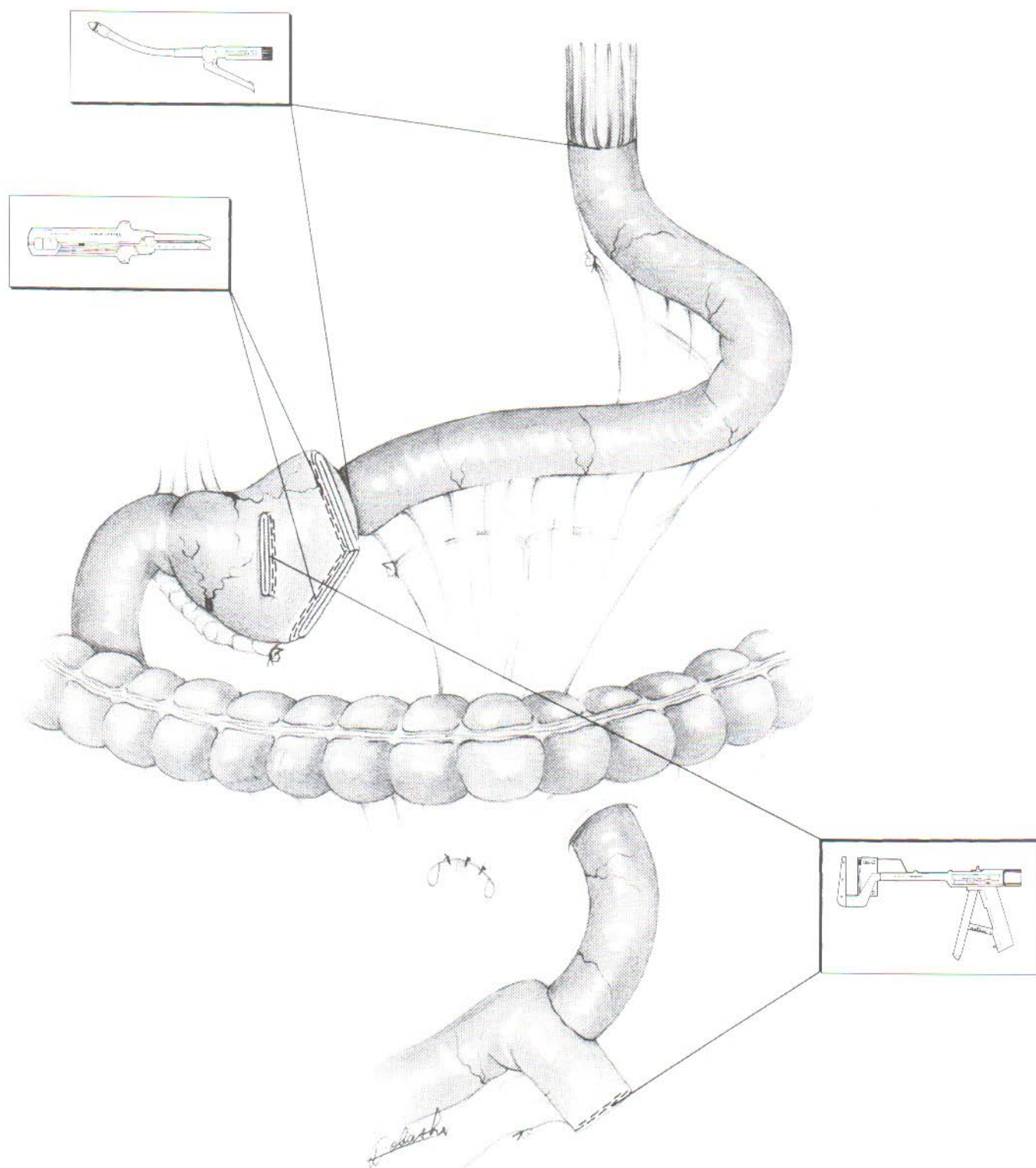
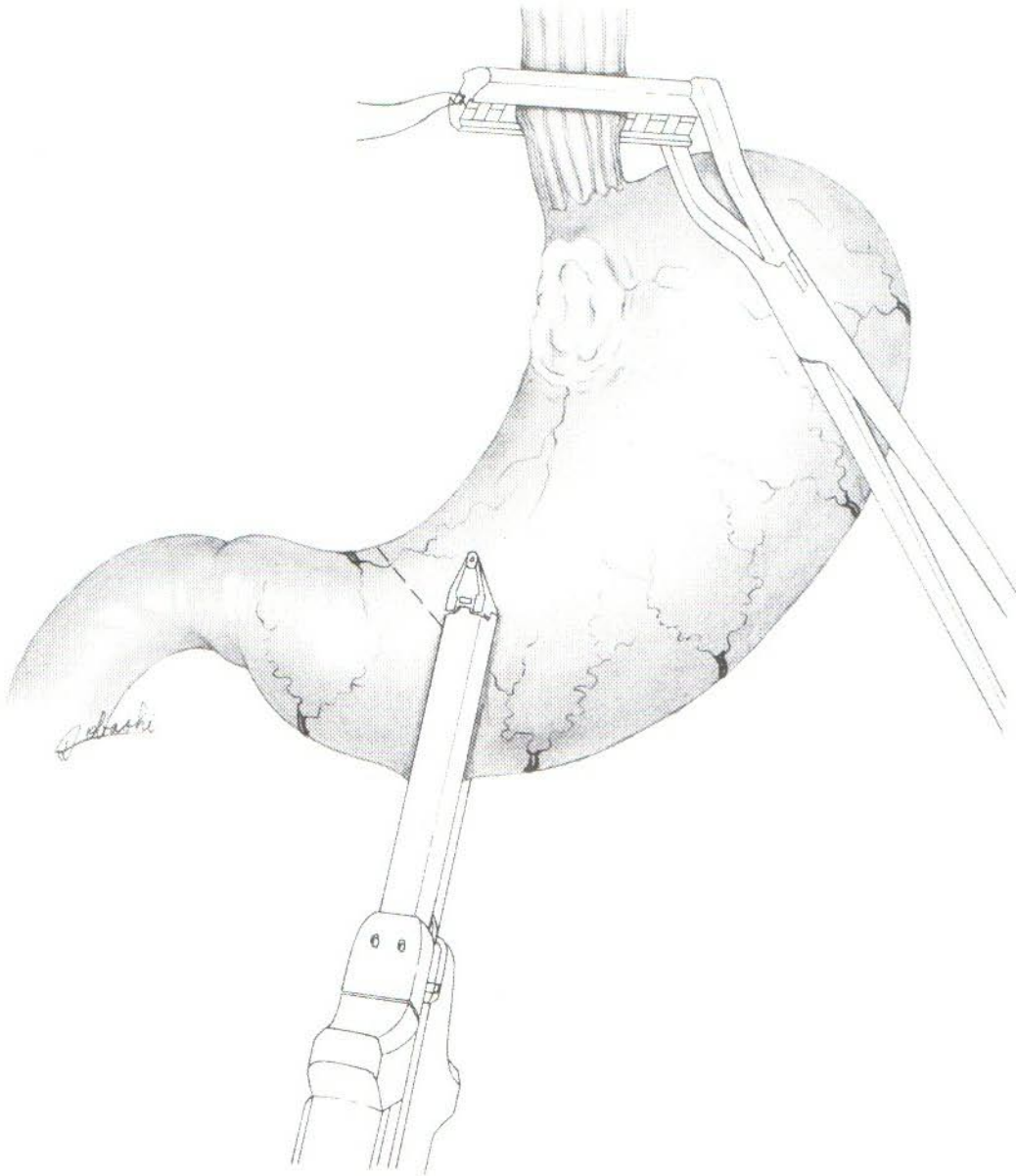


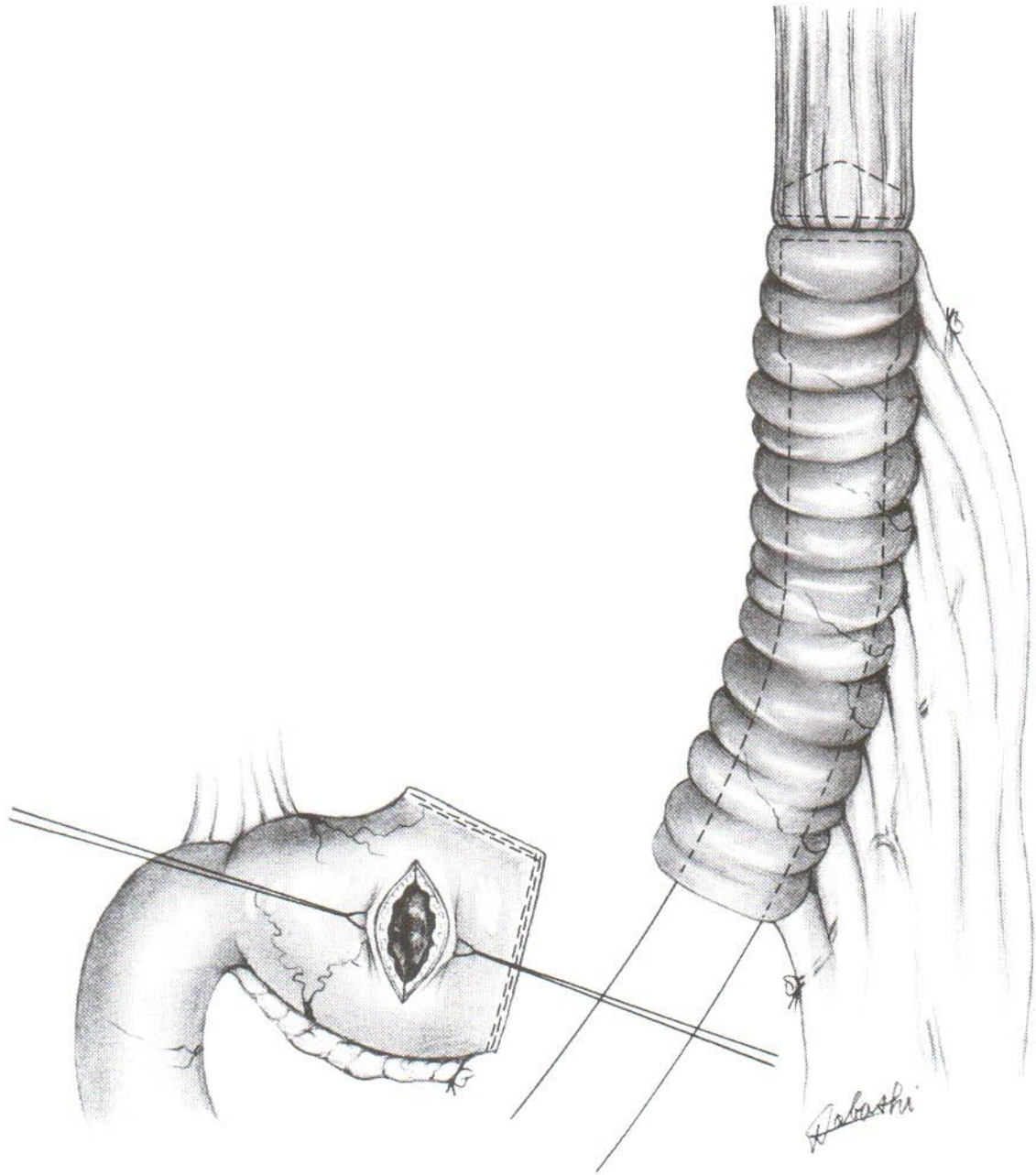
近端胃次全切除术后空肠间置术 Proximal subtotal gastrectomy with jejunal interposition





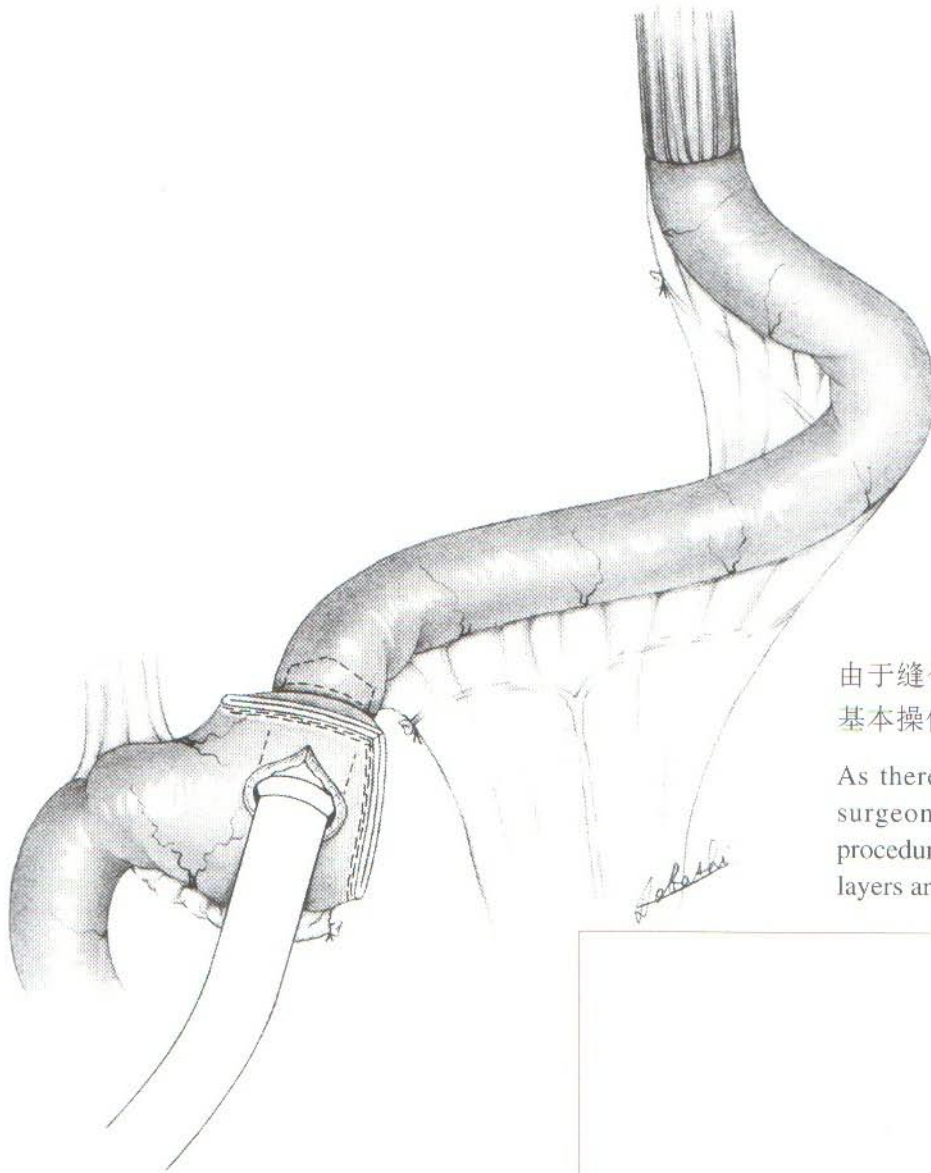
必须充分保持幽门部的血供，但在疑有淋巴结转移情况下则不适用。

The pyloric blood flow should be guaranteed. But that will not be the case if lymphatic metastasis is suspected.



由于食道壁较厚，应将食道全层结扎在砧头轴上。如果操作不顺利，可使用圈套器进行处理。

As the esophageal wall is relatively thick, the whole esophageal layer should be tied to the anvil shaft. A snare can be used when the manipulation cannot be done smoothly.



由于缝合部位多，必须认真重复进行基本操作，使全层组织都被缝合。

As there are several stapling sites, the surgeon has to repeat the same basic procedure carefully to ensure that all tissue layers are stapled.

