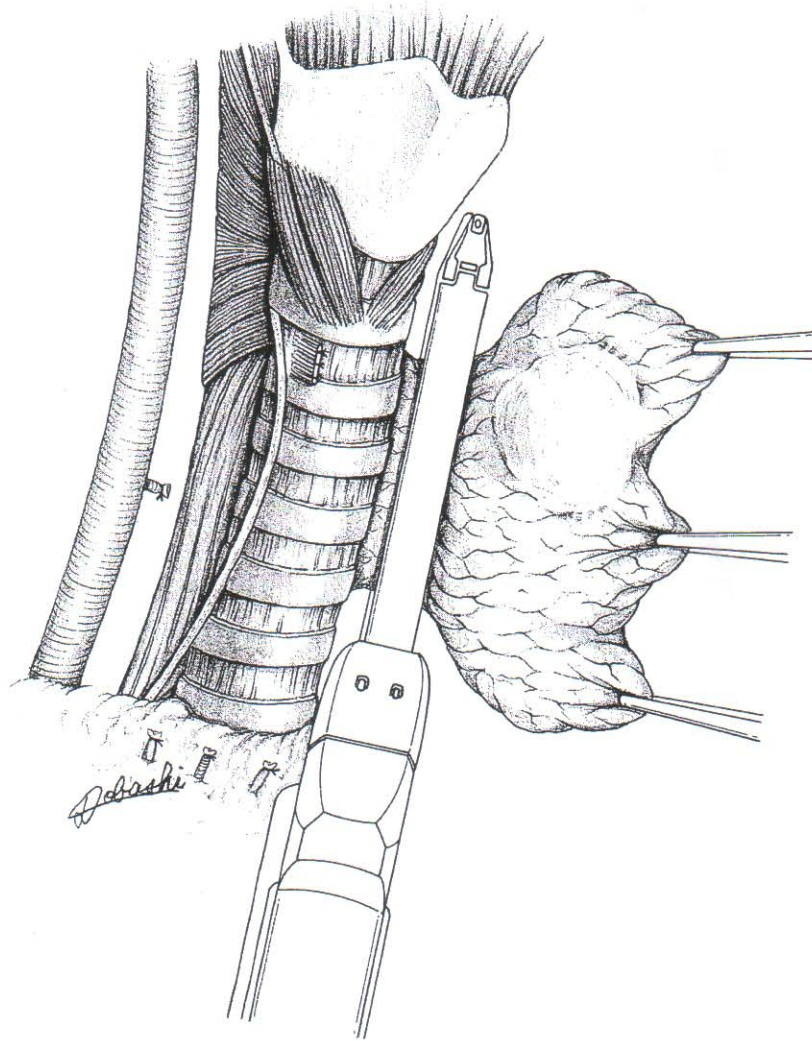
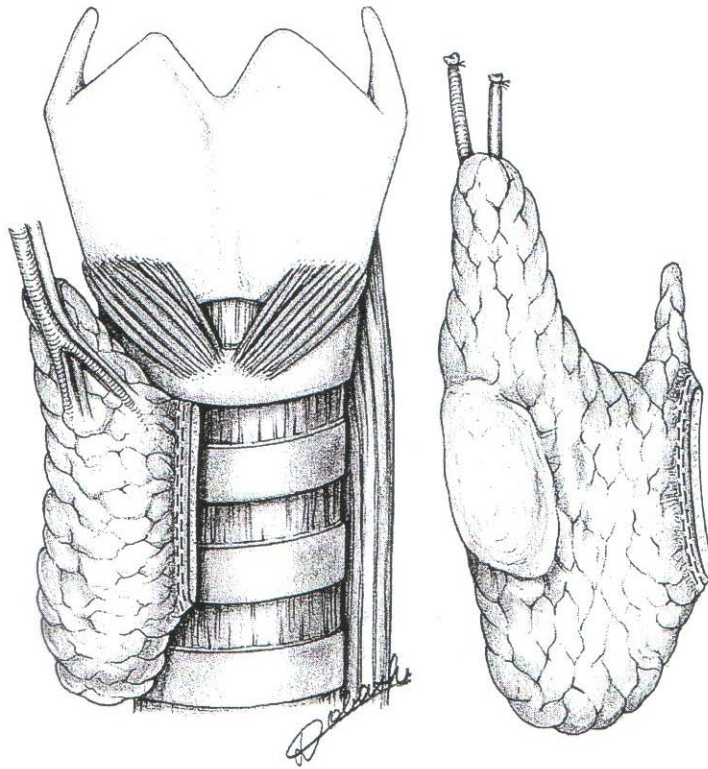


甲状腺腺叶切除术

Thyroid gland lobectomy





甲状腺切断面的出血在不能用缝合器止血的情况下，可用电刀止血。

Use electro-coagulation to control the bleeding of the resected plane of the thyroid gland, when the stapler cannot be used for hemostasis.